

**Report of Coroner's Physician to the  
Coroner of Winnebago County, Illinois**

I, Mark Peters M.D., have made a necropsy on the

body identified to me by the coroner of this county as being:

Name Seago, Kayla Date of Death 1-11-15

Place of Death (city, village, or twp.): Rockford, Illinois

Place of Examination (city, village, or twp.): Rockford, Illinois

In my opinion, the cause of death was as follows:

[Enter only one cause per line for (a), (b), and (c).]		APPROXIMATE INTERVAL BETWEEN ONSET AND DEATH
IMMEDIATE CAUSE		
(a) <u>Asphyxia</u> DUE TO, OR AS A CONSEQUENCE OF		
CONDITIONS, IF ANY, WHICH GAVE RISE TO IMMEDIATE CAUSE (a) STATING THE UNDERLYING CAUSE LAST.	(b) <u>Hanging</u> DUE TO, OR AS A CONSEQUENCE OF	
	(c) <u>N/A</u>	

OTHER SIGNIFICANT CONDITIONS CONTRIBUTING TO DEATH BUT NOT RELATED TO THE TERMINAL CONDITIONS GIVEN ABOVE:

None

My conclusions are based on the following observations and findings:

Coroner's field report, autopsy findings and toxicological analyses.

Date 1/12/2015 Signed  M.D.

Coroner's Physician

**INSTRUCTIONS**

1. Prepare this form in triplicate. Use typewriter or computer for all entries except signature
2. Sign original and first copy in pen and ink.
3. Mail original and first copy to the coroner. Retain last copy

## AUTOPSY REPORT

NAME: Seago, Kayla

CASE # 15-018

AGE: 24

SEX: Female

RACE: Caucasian

PRONOUNCED DEAD ON 01-11-15 AT 0503 HRS      COUNTY: Winnebago

AUTOPSY PERFORMED ON 01-12-15 AT 9:00 AM

DATE OF REPORT: 8/11/2015

### History

The following history was obtained from the Winnebago County Coroner's Office and indicates that the subject was found dead in her residence on January 11, 2015 and pronounced dead at 0503 hours. Her boyfriend stated that he found her hanging from a dog leash in the basement after being alerted by a text message she sent him.

The autopsy is performed at the Winnebago County Coroner's facility, Rockford, Illinois, on January 12, 2015 at 9:00 a.m. Emily Behnke and Bill Hintz of the Winnebago County Coroner's Office, a representative of the Winnebago County State's Attorney's Office, and two representatives of the Rockford Police Department were present at the autopsy.

### External

The body is received within a white body bag and is clad in socks, pants, belt, underwear, jacket, shirt and a bra. Multiple jewelry items are present on the subject.

The body is that of a well-developed, well-nourished white female of stated age 24 years, who is 64" in length and weighs 134 pounds. Rigor mortis is complete and fixed to an equal degree in all extremities. Purple, fixed lividity involves the posterior dependent portions of the body, except in areas exposed to pressure. The body is cold to the touch.

Scalp hair is blond and of normal distribution. The eyes are gray, pupils 8 mm in diameter, and normally formed. The corneas are clear and the conjunctivae show petechiae. The ears are normally formed and unremarkable. The nose is unremarkable. The left lower lip shows abrasion and laceration. Natural teeth are present in the upper and lower jaws. The tongue, buccal mucosa and pharynx are normal.

The chest is symmetrical. Breasts are normal and unremarkable. The abdomen is not protuberant and the back is unremarkable.

The extremities bilaterally are symmetrical and normally formed with all digits present and normally formed.

The perineum and anus are normal in appearance and the external genitalia are those of a normal adult female.

#### Evidence Of Resuscitation/Medical Intervention

EKG electrodes

#### Primary Pathological Findings

- I. Asphyxia due to hanging
  - A. Ligature abrasions present on the anterior and lateral sides of the neck, angled upward beneath the right ear, measuring up to 1 inch in width; more abrasions present on the left side than right
  - B. Petechiae, multiple, involving the periorbital skin and conjunctivae
  - C. Pulmonary vascular congestion and edema, mild, combined weight of lungs 890 grams
  - D. Focal hemorrhage in the soft tissue anterior to the superior horns of the thyroid cartilage; no evidence of fractures or other injuries

#### Secondary Findings

No evidence of other significant natural disease, injury, active infection, congenital anomaly, or pregnancy

Evidence Taken At Autopsy

One blood standard, filter paper, transferred to the Winnebago County Coroner's Office.

Photography

Autopsy photographs were taken by Emily Behnke.

Microscopic Findings

Appropriate sections of the internal organs are retained for subsequent histologic examination as may be indicated.

Toxicology

Blood, urine, and vitreous collected at autopsy.  
Specimens analyzed: blood, urine, and vitreous.

Laboratory Findings

Blood: alprazolam 85 ng/mL, ethanol 0.066% (w/v), fluoxetine 504 ng/mL, norfluoxetine 311 ng/mL, positive for caffeine

Urine: ethanol 0.148% (w/v)

Vitreous: ethanol 0.095% (w/v)

Opinion

Death is attributed to asphyxia due to hanging.



Mark Peters, M.D.  
Forensic Pathologist

GROSS FINDINGS AND ORGAN WEIGHTS

BODY CAVITIES

Pericardial: moist without adhesions  
Right Pleural: moist without adhesions  
Left Pleural: moist without adhesions  
Peritoneal: moist without adhesions

ORGAN SYSTEMS AND WEIGHTS

CARDIOVASCULAR

Heart: 300 grams

Epicardium: unremarkable

Endocardium: unremarkable

Coronary Arteries: unremarkable

Valves: unremarkable

Myocardium: unremarkable

Aorta: unremarkable

Vena Cava: unremarkable

RESPIRATORY

Right Lung: 490 grams

Left Lung: 400 grams

Pulmonary Arteries: unremarkable

Trachea: unremarkable

Bronchi: unremarkable

Pulmonary congestion: mild

Pulmonary edema: mild

Anthraxis: none

Emphysema: none

Atelectasis: none

Consolidation: none

ORGAN SYSTEMS AND WEIGHTS CONTINUED

ALIMENTARY

Esophagus: unremarkable  
Stomach: empty  
Intestines: unremarkable  
Appendix: unremarkable  
Pancreas: unremarkable  
Liver: 1470 grams; mild congestion  
Gallbladder: 20 cc of bile present

RETICULOENDOTHELIAL

Spleen: 130 grams  
Lymph nodes: unremarkable  
Bone marrow: unremarkable  
Thymus: unremarkable

GENITOURINARY

Right Kidney: 120 grams  
Left Kidney: 130 grams  
Ureters: unremarkable  
Urinary Bladder: 30 cc urine  
Uterus: unremarkable  
Ovaries, oviducts and vagina: unremarkable

ENDOCRINE

Thyroid: unremarkable  
Parathyroid: unremarkable  
Adrenal glands: unremarkable

NERVOUS

Brain: 1190 grams  
Injury: none noted  
Hemorrhage: none noted  
Edema: none  
Atrophy: none  
Arteries: unremarkable  
Spinal Cord: unremarkable  
Pituitary: unremarkable


MUSCULOSKELETAL

Skull/Spine: unremarkable  
Ribs: unremarkable  
Sternum: unremarkable  
Clavicles: unremarkable  
Extremities: unremarkable  
Pelvis: unremarkable  
Mandible/maxilla: unremarkable  
Diaphragm: unremarkable

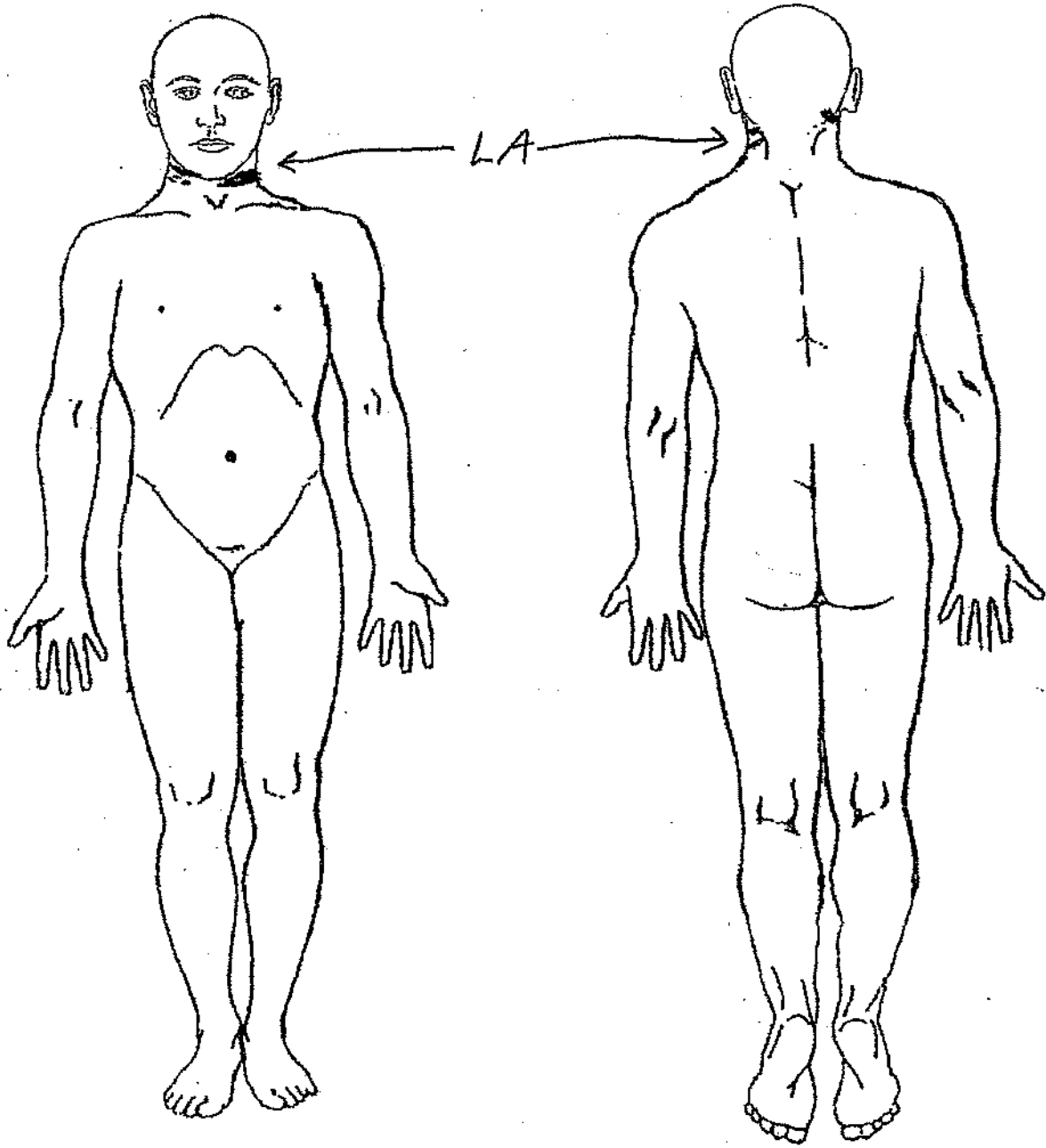
NECK CONTENTS

Strap muscles: unremarkable  
Soft tissue: hemorrhage, bilateral  
Carotid arteries: unremarkable  
Jugular veins: unremarkable  
Hyoid bone: unremarkable

Epiglottis: unremarkable  
Larynx: unremarkable  
Vocal cords: unremarkable  
Thyroid cartilage: unremarkable  
Cricoid cartilage: unremarkable



Mark Peters, M.D.  
Forensic Pathologist



Abbreviation:  
LA = Ligature abrasion

A handwritten signature in black ink, appearing to be 'J. Seago'.